

## EFFECT OF DISLOCATED AND TILTED CORRECTION GLASSES ON PERIMETRIC OUTCOME A simulation using ray-tracing

W. FINK<sup>1</sup>, U. SCHIEFER<sup>2</sup> and E.W. SCHMID<sup>1</sup>

<sup>1</sup>Institute for Theoretical Physics; <sup>2</sup> University Eye Hospital, Department II;  
Tübingen, Germany

Adequate correction is an essential prerequisite for precise perimetry. Therefore, not only the correct glasses have to be chosen, but also their positioning should be properly determined. Otherwise, a distortion of the stimulus grid, as well as a (area enlarging/reducing) distortion of the stimuli themselves, can occur. Therefore, scotomata may be simulated in visual fields which are purely optically evoked (so-called refraction scotoma<sup>1</sup>), because the light stimulus is mapped on an enlarged/reduced retinal area, thereby reducing/increasing light density.

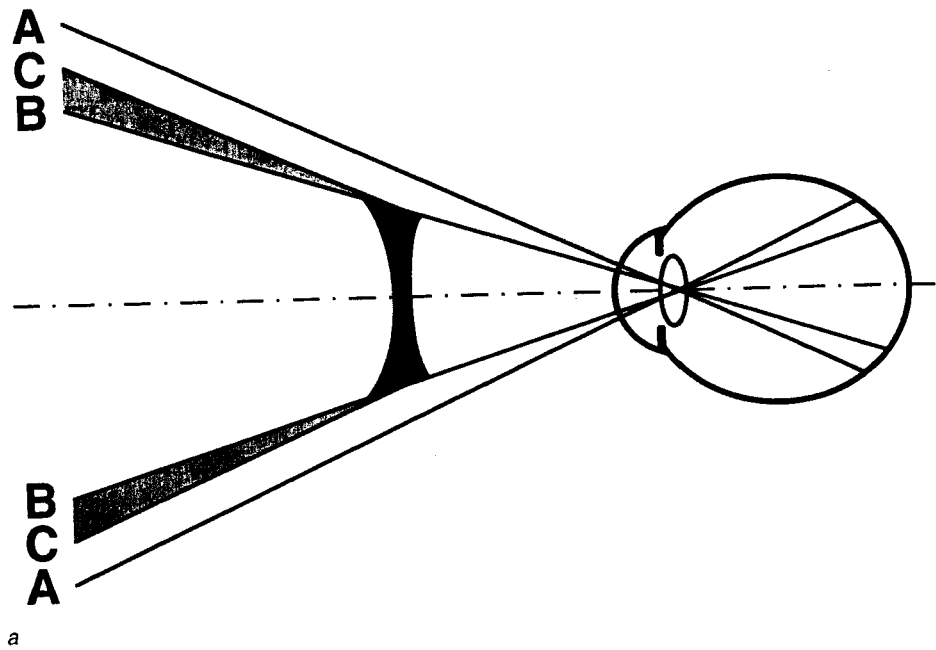
Ray-tracing<sup>2</sup> algorithms are capable of simulating, quite realistically, the optical properties of the human eye and other optical corrections (glasses, IOLs, contact lenses, etc.). Patterns of point sources are used as objects. Based on an improved Gullstrand eye model, the path of light rays is calculated between the point source and the retina through the refractive media obeying Snellius' law.<sup>3</sup> The image formed on the retina is projected back to a screen at the distance of the object so as to simulate image interpretation by the brain.

Even though the correct glasses may be positioned in the right way, the refraction scotomata mentioned above can also occur in the presence of high ametropia, namely high myopia and hyperopia, e.g., aphakia. In the case of high myopia, regional polyopia ('Bildverdoppelung') is caused (see, Fig. 1a), whereas in the case of high hyperopia, an annular scotoma can occur (see, Fig. 1b).<sup>4,5</sup>

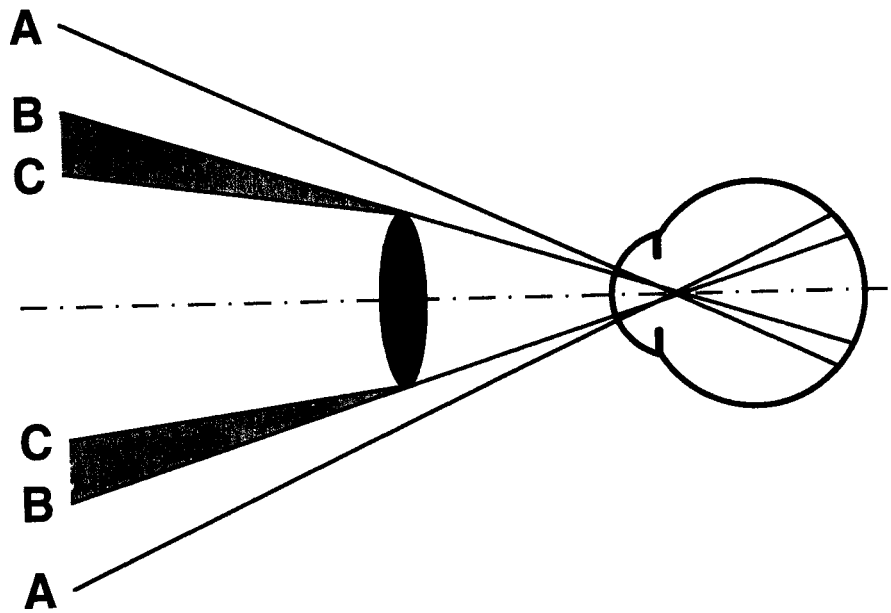
To show this, we have calculated the effects on the mapping of a stimulus grid of the Tübingen automated perimeter (TAP). We have demonstrated changes in both size and spatial translation of the blind spot in myopic and hyperopic patients. As far as the perimetric results are concerned, the size of the blind spot is increased and its position is transferred to higher eccentricities for myopic patients. This is due to the wide-angle effect of a bi-concave correction glass. Therefore, the blind spot is detected with stimuli of higher eccentricities compared to an emmetropic normal. However, in the hyperopic case, the size of the blind spot is reduced, and its position is transferred to lower eccentricities because of the magnification effect of a

*Address for correspondence:* Dr. W. Fink, Institute for Theoretical Physics, Auf der Morgenstelle 14, D-72076 Tübingen, Germany

*Perimetry Update 1996/1997, pp. 201-204*  
*Proceedings of the XIIth International Perimetric Society Meeting*  
*Würzburg, Germany, June 4-8, 1996*  
*edited by M. Wall and A. Heijl*  
© 1997 Kugler Publications bv, Amsterdam/New York



a



b

*Fig. 1a.* Formation of purely optically evoked regional polyopia. *b.* Formation of purely optically evoked annular scotoma. *c.* Original TAP stimulus grid. *d.* Distortion of the stimulus grid and of the stimuli - simulated (eye-glass corrected myopia of -11 D). *e.* Distortion of the stimulus grid and of the stimuli - simulated (eye-glass corrected hyperopia/aphakia of +13.5 D).

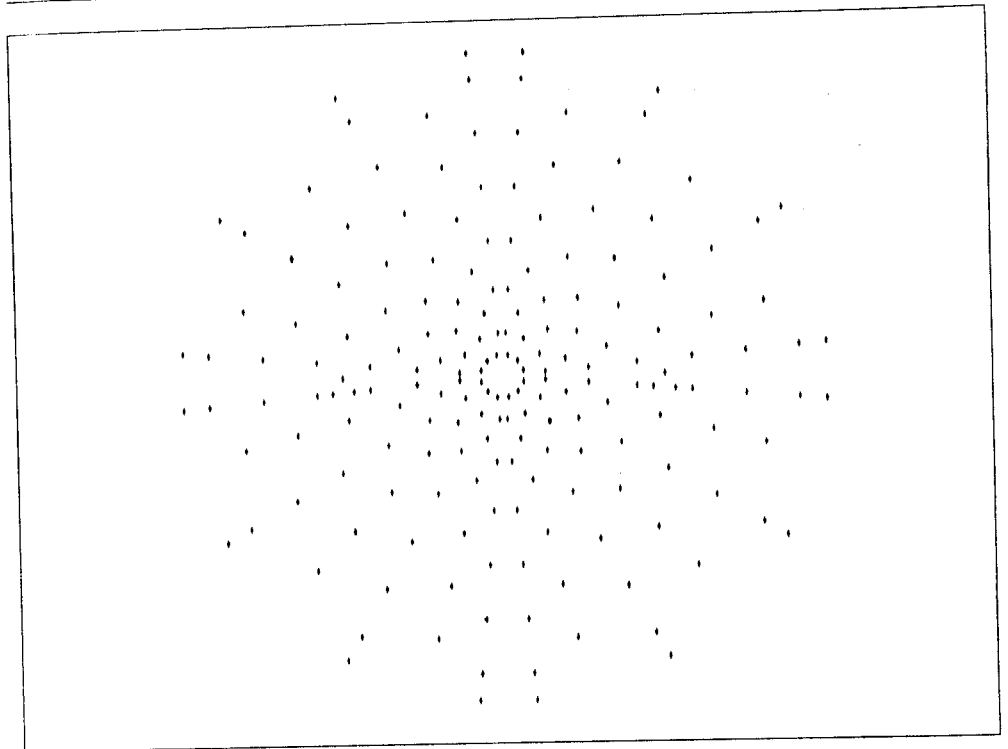
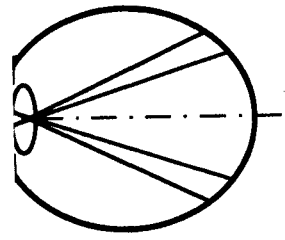


Fig. 1c.

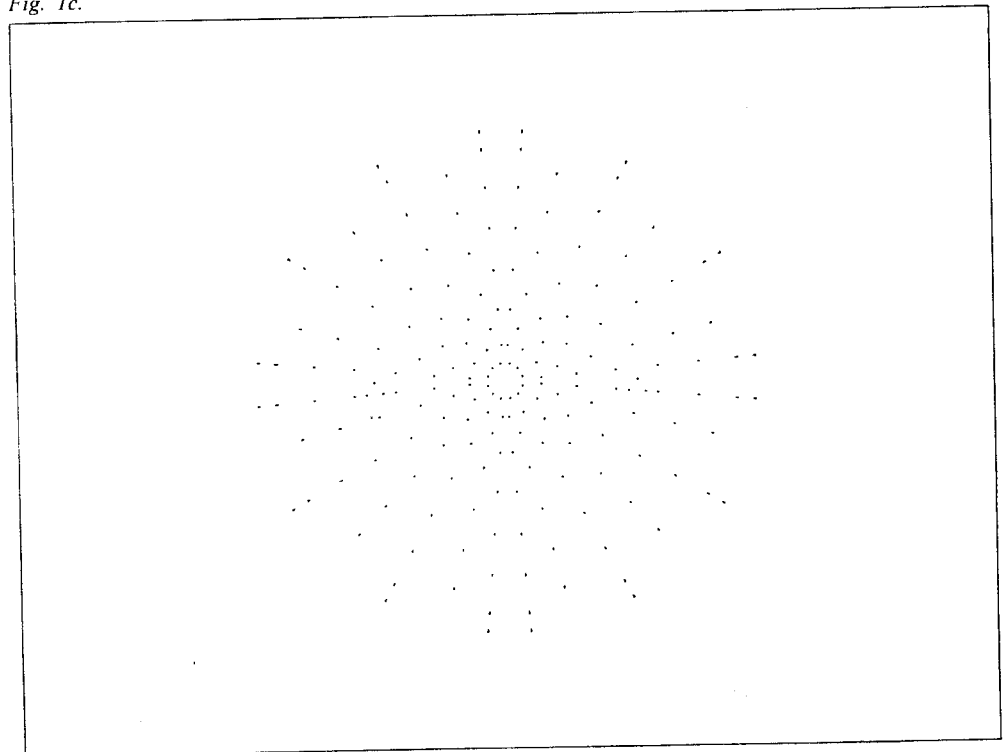
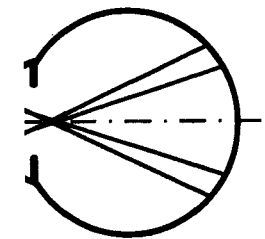


Fig. 1d.

Formation of purely optically  
of the stimulus grid and of the  
of the stimulus grid and of  
3.5 D).

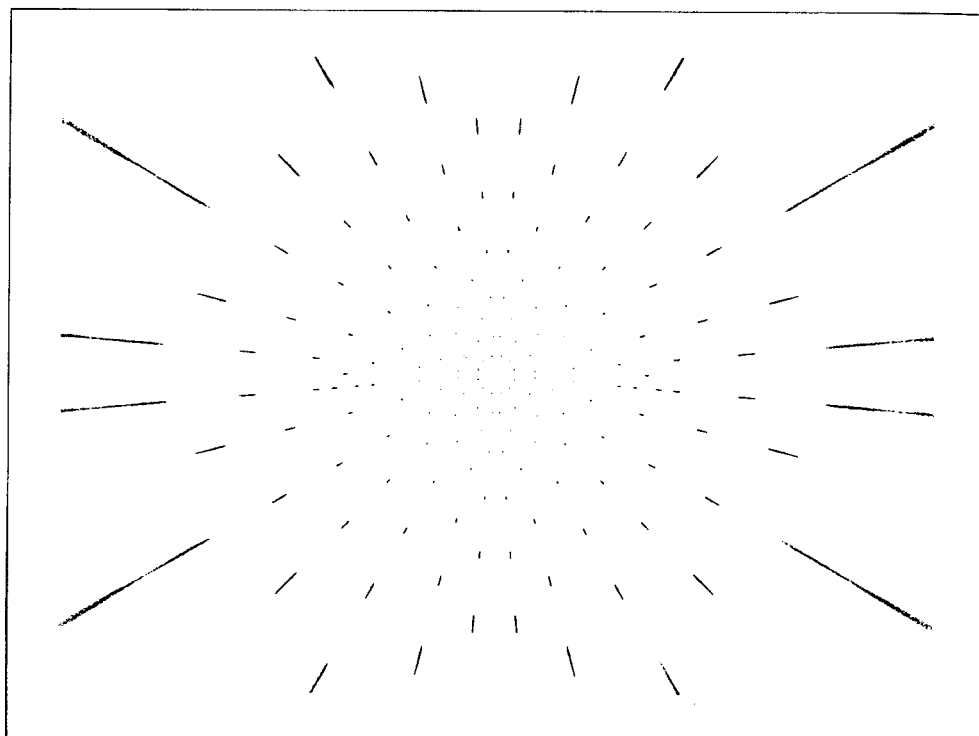


Fig. 1e.

bi-convex correction glass. Thus, detection of the blind spot is performed with stimuli of lower eccentricities compared to an emmetropic normal (see, Figs. 1c, d and e).

Furthermore, it is possible to visualize the influence of tilted and vertically and horizontally dislocated correction glasses, resulting in an asymmetric distortion of both the stimulus grid and the stimuli themselves. In perimetry, a reduction of the distortions shown so far may be achieved by using contact lenses for optical correction instead of eye-glasses.

Ray-tracing is a useful tool for visualization and analysis in ophthalmological research. Therefore, it may contribute to a better understanding of the effects of optically-caused mapping errors on perimetric results.

### References

1. Aulhorn E, Durst W: Die Bedeutung der Perimetrie des blinden Flecks für die klinische Diagnostik. *Fortschr Ophthalmol* 84:631-634, 1987
2. Born M, Wolf E: *Principles of Optics*, 5th edn. Oxford: Pergamon Press 1975
3. Fink W, Frohn A, Schiefer U, Schmid EW, Wendelstein N: A ray tracer for ophthalmological applications. *Ger J Ophthalmol* 5:118-125, 1996
4. Fink W, Frohn A, Schiefer U, Schmid EW, Wendelstein N, Zrenner E: Visuelle Abbildung bei hohen Ametropien: Computergestützte Simulation mittels strahlenoptischer Rechnungen. *Klin Mbl Augenheilk* 208:472-476, 1996
5. *Handbuch für Augenoptik*, 3rd Edn, p 180. Oberkochen, Germany: Carl Zeiss 1987

## APPARENT GLAUCOMATOUS VISUAL FIELD DEFECTS CAUSED BY DERMATOCHALASIS

M.K. BIRCH, A.S. KOSMIN and P.K. WISHART

*Glaucoma Clinic, St Paul's Eye Unit, Royal Liverpool University Hospital, Liverpool, United Kingdom*

*Purpose:* To quantify the effect of dermatochalasis on the central visual field and thus to assess the potential of this common upper lid abnormality to confound diagnostic perimetry in glaucoma.

*Methods:* We identified a series of ocular hypertensive patients with dermatochalasis who demonstrated reproducible central field loss by Humphrey automated perimetry Program 24-2. We confirmed dermatochalasis as the cause of the field loss by demonstrating reversal following taping up the upper lid or blepharoplasty.

*Results:* Central field loss due to dermatochalasis was identified in 12 eyes of seven ocular hypertensive patients. All demonstrated restriction of the superior field, most marked temporally in ten eyes and in continuity with the blind spot in five eyes. Extension of the defect below the horizontal meridian was seen in four eyes. The average mean deviation was -5.88 dB and average mean sensitivities were reduced at all points including fixation in the superior vertical meridian. The degree of depression increased with eccentricity from fixation.

*Conclusions:* Dermatochalasis causes more marked restriction of the superior central field than equivalent ptosis. Consequently cosmetically mild dermatochalasis may cause marked central field defects which may confound diagnostic perimetry in glaucoma.

### References

1. Hacker HD, Hollsten DA: Investigation of automated perimetry in the evaluation of patients for upper lid blepharoplasty. *Ophthalmic Plastic Reconstruct Surg* 8(4):250-255, 1992
2. Meyer DR, Stern JH, Jarvis JM: Evaluating the visual field effects of blepharoptosis using automated static perimetry. *Ophthalmology* 100:651-659, 1993

*Address for correspondence:* M.K. Birch, MD, Glaucoma Clinic, St Paul's Eye Unit, Royal Liverpool University Hospital, Liverpool, UK

*Perimetry Update 1996/1997, p. 205*  
*Proceedings of the XIIth International Perimetric Society Meeting*  
*Würzburg, Germany, June 4-8, 1996*  
*edited by M. Wall and A. Heijl*  
© 1997 Kugler Publications bv, Amsterdam/New York

blind spot is performed with  
as normal (see, Figs. 1c, d

of tilted and vertically and  
asymmetric distortion of  
perimetry, a reduction of the  
of contact lenses for optical correc-

analysis in ophthalmological  
standing of the effects of

blinden Flecks für die klinische

tion Press 1975  
ray tracer for ophthalmological

mer E: Visuelle Abbildung bei  
enoptischer Rechnungen. Klin

ny: Carl Zeiss 1987